



PATIENT

Rocky Steigerwald

PRESENTING CLINICAL SIGNS

History: Grade I-II/VI heart murmur. Echocardiogram prior to anesthesia for neutering.

SPECIES

Canine

ECHOCARDIOGRAM FINDINGS

2D, m-mode, color flow and Doppler imaging is available.

Left ventricle: The LV diameter is normal with adequate myocardial function. LV wall thicknesses are normal.

BREED

Pug Mix

Left atrium: The left atrium is normal.

Mitral valve: The mitral valve is normal with no prolapse into the left atrial lumen. Trivial MR.

SEX

Male Intact

Aortic valve/Aorta: The aortic valve is normal in morphology and mobility. Normal aortic outflow velocity; laminar flow. No aortic insufficiency.

Right ventricle: Normal right ventricular diameter and morphology indicating no overt evidence of pulmonary arterial hypertension.

Right atrium: Normal RA dimension.

AGE

6 months

Tricuspid valve: The tricuspid valve appears normal with trivial physiologic tricuspid regurgitation.

Pulmonic valve/Pulmonary artery: The pulmonic valve is normal in morphology and mobility. No pulmonic insufficiency. Normal RVOT velocity; laminar flow.

WEIGHT

12.89lbs

Pericardium/other: No pericardial or pleural effusion noted. No obvious cardiac masses.

Heart rhythm: ECG reveals a sinus rhythm with an average HR of 120bpm.

2-Dimensional Measurements

Doppler Measurements

INTERPRETED BY

Maggie Machen
Lamy, DVM
DACVIM (Cardiology)

Ao diam (cm)	1.3
LA diam (cm)	1.6
LA:Ao (Swe)	1.2
IVS thickness (cm)	0.6
LVID diastole (cm)	2.2
PW thickness (cm)	0.7
LVID systole (cm)	1.6
FS (%)	28

PV Vmax (m/s)	0.8
AoV Vmax (m/s)	1.1
MR Vmax (m/s)	NM
TR Vmax (m/s)	NM
TR PG (mmHg)	NA

IMAGING

PERFORMED BY

Pamela Harrigan,
RDCS

INTERPRETATION OF THE FINDINGS

Overtly normal cardiac dimensions and function, with no obvious dysfunction or dilation of the left heart. No significant valvular leaks are visualized (trivial MR/TR are considered physiologic), and no evidence of pulmonary hypertension. No obvious congenital issues are visualized, and a flow murmur suspected. Prognosis is open at this time.

HOSPITAL NAME

Airport Animal
Hospital

RECOMMENDATIONS

- In an asymptomatic dog without obvious structural disease, no cardiac medications are clearly indicated.
- No cardiac contraindication for general anesthesia.
- Monitor for development of a cough, labored breathing, exercise intolerance or collapse episodes.

REFERRING VET

Dr. Gudluru

INVOICE

30395

DATE

4/21/23



PATIENT

Rocky Steigerwald

SPECIES

Canine

BREED

Pug Mix

SEX

Male Intact

AGE

6 months

WEIGHT

12.89lbs

INTERPRETED BY

Maggie Machen Lamy, DVM
 DACVIM (Cardiology)

IMAGING PERFORMED BY

Pamela Harrigan, RDCS

HOSPITAL NAME

Airport Animal Hospital

REFERRING VET

Dr. Gudluru

INVOICE

30395

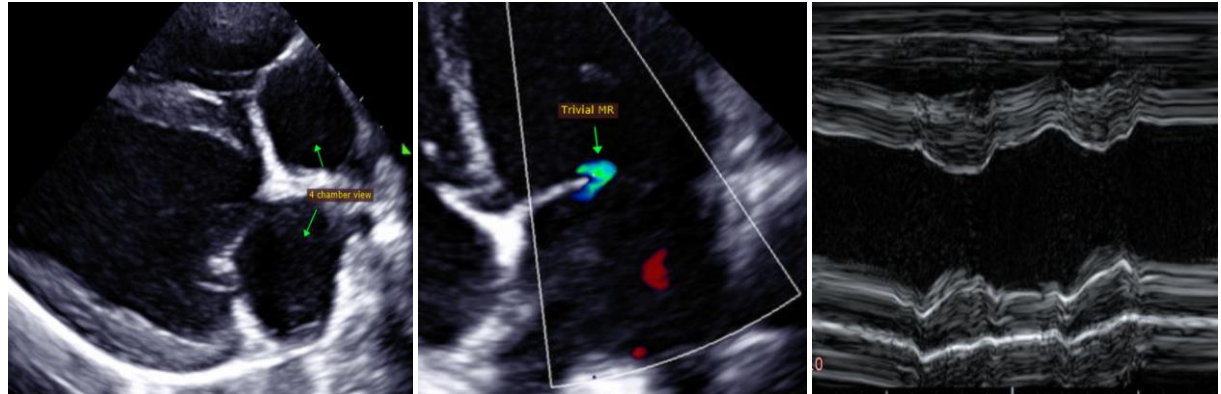
DATE

4/21/23

PLAN

- Assuming the murmur persists, recommend conservative monitoring with a recheck echocardiogram in 6-12 months, sooner if any development of clinical signs or the murmur progresses significantly in the interim.

IMAGES



The information and recommendations provided are based on the images presented by the referring veterinarian. No evaluation can be communicated regarding pathology that was not visible in the image/video clips provided.

Thank you for this referral. This report was generated using transcription software, and minor dictation errors may be present. If the clinical or image interpretation does not parallel your findings or if I can be of any further assistance, please contact me.

Maggie Machen Lamy, DVM
 Diplomate of the American College of Veterinary Internal Medicine (Cardiology)
 info@sonopath.com

Echocardiogram performed by: Pamela Harrigan, RDCS
 Pet Animal Ultrasound Service (4paus.com)